

## See You There:

9 may 2015

Cremona, Italy

**Corso di Formazione  
Patologie tiroidee:  
diagnostica  
e trattamento  
medico e chirurgico**

5-6 June 2015

Pisa, Italy

**International  
School of Thyroid  
Ultrasonography  
"Advanced practical  
thyroid ultrasound  
course: Focus on  
diagnostic  
elastosonography and  
laser treatment of  
thyroid nodules"**

## The percutaneous laser ablation in the treatment of hyperfunctioning thyroid nodules



**Dr. Daniele Barbaro**

Director of Endocrinology Department  
ASL 6 Livorno

[danielebarbaro1970@libero.it](mailto:danielebarbaro1970@libero.it)

Percutaneous Laser Ablation Therapy (LAT) is the elective treatment for benign, non-functioning thyroid nodules associated with compressive phenomena in patients who cannot or do not want to be treated surgically. As is known, various studies have demonstrated significant reductions by more than 50% in nodular volume in the majority of patients and in one of the latest studies published, this effect was stable at the 3-year follow-up (Papini et al JCEM 2014). A less debated situation for which fewer studies have been conducted, is the use of LAT in hyper-functioning nodules. In fact, in these nodules the purpose is the possible volumetric reduction, but also and above all, the normalization of the free hormones if elevated, and/or the normalization of the TSH. The treatment of hyper-functioning nodules is decidedly more complex as it requires the almost total destruction of the nodule otherwise a certain thyroid hormone secretion remains. In a study at the centre in Livorno and published in 2007 in the journal, *Endocrine Practice*, conducted on a small cohort of 18 patients with hyper-functioning nodules (pretotoxic in 13 cases and with high FT4 and/or FT3 in 5 cases) we reported the increase and normalization of the TSH in all the pre-toxic cases with a reduction in the free fractions in the other cases.

In another study by Døssing published in the *European Journal of Endocrinology* in 2007, an assessment was made of treatment with LAT versus standard treatment with  $^{131}\text{I}$ . The treatment with LAT showed the resuming of the normal TSH in 50% of cases (7 out of the 14 treated) with a less positive result than the treatment with  $^{131}\text{I}$  in which there was normalization in all cases (15 out of 15). In addition, in the patients treated with  $^{131}\text{I}$  there was also a reduction in the extranodular volume and hypothyroidism developed in two cases, obviously due to a partial uptake of the

radioisotope also by the normal thyroidal parenchyma.

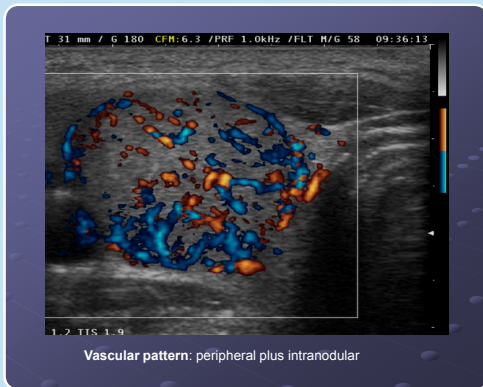
From 2004 up until today, a total of 91 other hyper-functioning nodules have been treated in our centre (80 pretotoxic and 11 already with elevated free fractions). Single nodules were treated in 49 cases, while the remaining patients were

suffering from multi-nodular goitre but in which the scintigraphic image clearly showed a single hyper-functioning nodule. In all the pretotoxic nodules there was an increase in the TSH and complete normalization in 72% of cases, with the best response in nodules sized < 9 mL, in cases of low, but still not suppressed TSH, and in cases of single nodules (unpublished data).

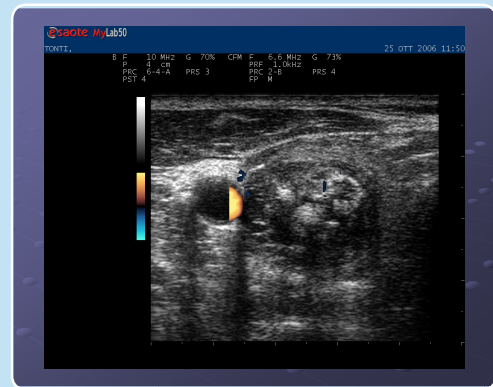
Therefore, in the light of our experience, hyper-functioning nodules may represent an indication for treatment with LAT. The pretotoxic nodules are those in which LAT has an excellent likelihood of success. In particular, it can be electively used in the treatment of smaller-sized or single nodules and those with only slightly lower TSH and in which scintigraphy does not show complete suppression of the extranodular parenchyma. In fact, in these cases, the development of hypothyroidism is possible after  $^{131}\text{I}$  treatment. On the other hand, these types of nodules can give nuanced symptoms of hyperthyroidism, especially cardiological symptoms in the elderly. For these reasons, the use of LAT probably represents the best therapeutic option in these nodules.

This is obviously also applicable in patients who do not wish to undergo treatment with  $^{131}\text{I}$  or surgery, or in special cases as in patients with high iodine intake. Two cases of patients with hyper-functioning nodules and a high cardiovascular and surgical risk, under treatment with amiodarone that prevented the administration of  $^{131}\text{I}$ , were also treated in our centre with excellent results (Figures 1 and 2).

To conclude therefore. Hyper-functioning nodules can be effectively treated with LAT. The nodules that are candidates for this treatment are the smaller-sized ones and those with still normal free fractions above all if TSH is not yet suppressed.



**Figure 1.** Color-doppler ultrasound of the nodule before LTA (4 fibers, 4 W, 1800 Joule)



**Figure 2.** Post treatment color doppler ultrasound that show absence of vascularization

## Laser Interstitial Thermo-Therapy (LITT) of breast cancer: preliminary experience at the Careggi University Hospital of Florence.



**Jacopo Nori<sup>a</sup>, Dalmar Abdulcadir<sup>a</sup>, Elisabetta Giannotti<sup>a</sup>, Giulia Bicchierai<sup>a</sup>, Diego De Benedetto<sup>a</sup>, Donato Casella<sup>b</sup>.**

<sup>a</sup>Diagnostic Senology Unit, AOU Careggi, Largo G. A. Brambilla 3 , 50134 Florence, Italy

<sup>b</sup>Breast Unit, Department of Surgery and Translational Medicine, AOU Careggi, Largo G. A. Brambilla 3 , 50134 Florence, Italy

[jakopo@tin.it](mailto:jakopo@tin.it)

### Background

Breast cancer is the most frequent cancer site in women (28.8% of all cancer sites), with an estimated lifetime risk of 1/9 women [1,2].

Widespread screening programs have resulted in an increased number of diagnosed small tumors [3], leading to less invasive surgical techniques [4,5].

Therefore, in the future a subgroup of patients might benefit from the local ablation of newly discovered tumors without undergoing surgical procedures.

We report our preliminary experience in using ultrasound-guided Laser Interstitial Thermo-Therapy (LITT) with a single fiber for the local ablation of breast carcinomas in 6 selected not-operable patients.

### Material and methods

The medical ethical committee approval was obtained for this study and written informed consent of patients was required. The six patients were selected by a multidisciplinary group of

radiologists, surgeons, radiotherapists and oncologists and were considered inoperable due to comorbidities that contraindicated general anesthesia or because of a refusal of surgery. The inclusion criteria were : a) diagnosis of invasive ductal carcinoma (IDC) with core-needle biopsy b) tumor visible on ultrasound c) patients' ability to lie still for a minimum of 15 min during treatment d) tumors located more than 1 cm from the skin and from the chest wall. All patients were studied with mammography, ultrasound and breast MRI before treatment. The size of the lesions ranged from 7 mm to 50 mm (mean of 25 mm).

Treatments were performed using the laser ablation system developed by Elesta (ECHOLASER XVG) with a single flat-tip optical fiber inserted into a 21-G (0.8 mm) needle. The LITT system was set to supply a power of 5 Watts for a maximum of 1800 Joules. We used sonographic guidance in all cases with a 13 MHz linear transducer. The treatments were all performed in the ultrasound room.

A mixture of lidocaine (10 cc) and ropivacaine (10 cc) was injected under the overlying skin and around the lesion using

ultrasound as guidance. A 21-G needle was inserted, under sonographic guidance, at the center of the lesion and then the laser fiber was positioned inside the needle.

Follow-up included post-operative clinical examination after 1 week and an ultrasound evaluation of the treated lesions after 1 week, 3 months, 6 months and 12 months. Breast MRI was performed after 12 months from the laser treatment.

Post-treatment core-needle biopsies were performed from the scar areas harvesting a mean number of 8 cores (6-10 cores) to rule out the presence of viable tumor cells.

## Results

The ablation rate was assessed considering the presence and the extension of enhancement at the breast MRI in comparison to pre-treatment MRI examinations. In addition, core needle biopsies were performed in case of suspicious MRI or US features to determine the presence of residual malignant cells. The value of the mean ablation rate resulted to be 83.3%.

## Discussion

There are only a very few studies regarding LITT for the treatment of breast cancer [6;7;8;9].

Those lesions smaller than 15 mm were completely ablated and no recurrence was seen after 12 months; therefore we can affirm that the settings used (1 fiber, 5 W and 1800 J) are suitable for the treatment of these small tumors. Lesions larger than 15 mm might be fully ablated using a multi-fiber technique similarly to the laser ablation of hepatocellular carcinoma [10;11].

Breast MRI and core-needle biopsy were also necessary before treatment to exclude the presence of intraductal component or invasive lobular carcinoma.

In addition, LITT was well accepted by the entire patient population as an alternative to surgery, and showed a low rate of complications with only 1 patient (16.7%) who had a mild skin burn that was medically treated.

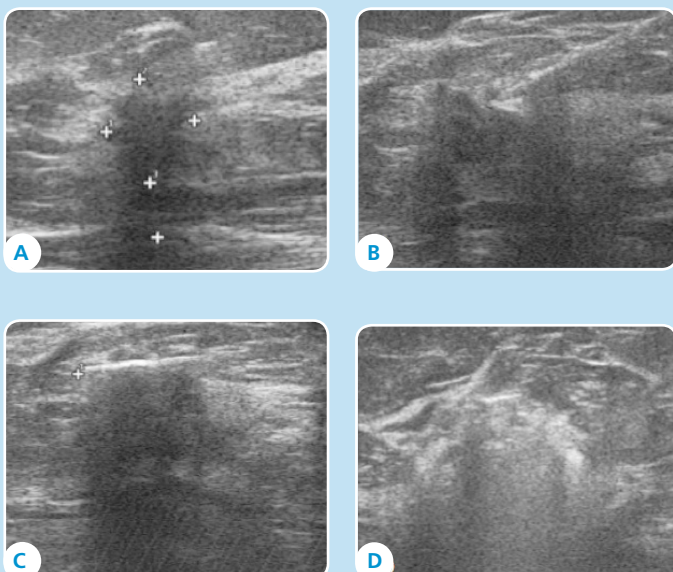
The procedure did not leave any retraction or scar on the skin on any patients.

## Conclusions

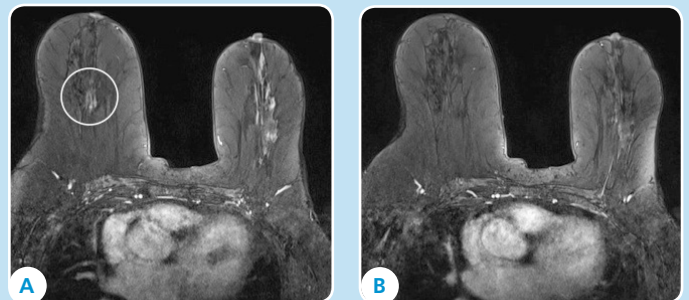
In conclusion, LITT could be an effective technique to locally control the growth of breast invasive carcinomas in inoperable patients, such as elderly patients considering the low rate of complications. Moreover, LITT showed to be also an effective procedure to completely ablate lesions smaller than 15 mm using a single fiber. A multi-fiber technique could allow the ablation of larger lesions.

## References

1. Ferlay J, Steliarova-Foucher E, Lortet-Tieulent J, et al. Cancer incidence and mortality patterns in Europe: estimates for 40 countries in 2012. *Eur J Cancer*. 2013;49(6):1374-403.
2. Jemal A, Siegel R, Ward E, et al. Cancer statistics, 2007. *CA Cancer J Clin*. 2007;57(1):43-66
3. Elmore JG, Armstrong K, Lehman CD, et al. Screening for breast cancer. *JAMA*. 2005; 293(10):1245-1256
4. Fisher B, Redmond C, Poisson R, et al. Eight-year results of a randomized clinical trial comparing total mastectomy and lumpectomy with or without irradiation in the treatment of breast cancer. *N Engl J Med*. 1989;320:822-8
5. Veronesi U, Cascinelli N, Mariani L, et al. Twenty-year follow-up of a randomized study comparing breast-conserving surgery with radical mastectomy for early breast cancer. *N Engl J Med*. 2002;347:1227-32
6. van Esser S, Stapper G, van Diest PJ, et al. Ultrasound-guided laser-induced thermal therapy for small palpable invasive breast carcinomas: a feasibility study. *Ann Surg Oncol*. 2009;16(8):2259-63.
7. Haraldsdóttir KH, Ivarsson K, Götberg S, et al. Interstitial laser thermotherapy (ILT) of breast cancer. *Eur J Surg Oncol*. 2008;34(7):739-45.
8. Bloom KJ, Dowlath K, Assad L. Pathologic changes after interstitial laser therapy of infiltrating breast carcinoma. *Am J Surg*. 2001;182(4):384-8.
9. Dowlathshahi K, Francescatti DS, Bloom KJ. Laser therapy for small breast cancers. *Am J Surg*. 2002;184(4):359-63.
10. Pacella CM, Bizzarri G, Magnolfi F, et al. Laser thermal ablation in the treatment of small hepatocellular carcinoma: results in 74 patients. *Radiology*. 2001 Dec;221(3):712-20.
11. Francica G, Petrolati A, Di Stasio E, et al. Effectiveness, safety, and local progression after percutaneous laser ablation for hepatocellular carcinoma nodules up to 4 cm are not affected by tumor location. *AJR Am J Roentgenol*. 2012 Dec;199(6):1393-401.



**Figure 1.** Ultrasound-guided LITT of a 15 mm invasive ductal carcinoma: **A)** Lesion to treat. **B)** Insertion of the needle inside the lesion. **C)** Positioning of the needle and the laser fiber. **D)** Sonographic appearance of the lesion after the treatment.



**Figure 2.** Contrast-enhanced T1 with fat saturation images showing the fully ablated lesion shown in Fig.1: **A)** MRI performed before treatment (white circle). **B)** MRI performed after 12 months showing no enhancement or suspicious feature

## The corner of the engineer

### Why does Echolaser use a 1064nm wavelength for the laser ablation treatment?



**Luca Breschi PhD**

Elesta R&D Manager

[l.breschi@elesta-echolaser.com](mailto:l.breschi@elesta-echolaser.com)

The interaction of the Laser radiation with biological tissue depends on optical properties of the biological tissue (absorption and scattering).

The **absorption** property of tissue varies with tissue constituents especially water, fat, collagen, and their combination ratio. The absorption coefficient represents the part of radiated energy which is convert in heat and hence induce a temperature increase and is defined as the probability of photon absorption in tissue per unit path length.

Moreover optical **scattering** occurs due to mismatches in refractive index of the different tissue components, ranging from cell membranes to whole cells. Light scattering in biological tissue is denoted by the scattering coefficient, which is defined as the probability of photon scattering in tissue per unit path length.

A combination of absorption and scattering coefficient leads to **optical penetration** that is the properties of light to penetrate tissue in depth. For the efficacy in terms of volume of ablation the most important thing is obtain an excellent penetration that is a balance of scattering and absorption coefficients.

How can we increase optical penetration?

Since scattering and absorption coefficient depends on the wavelength the answer is choosing the most appropriate Laser wavelength.

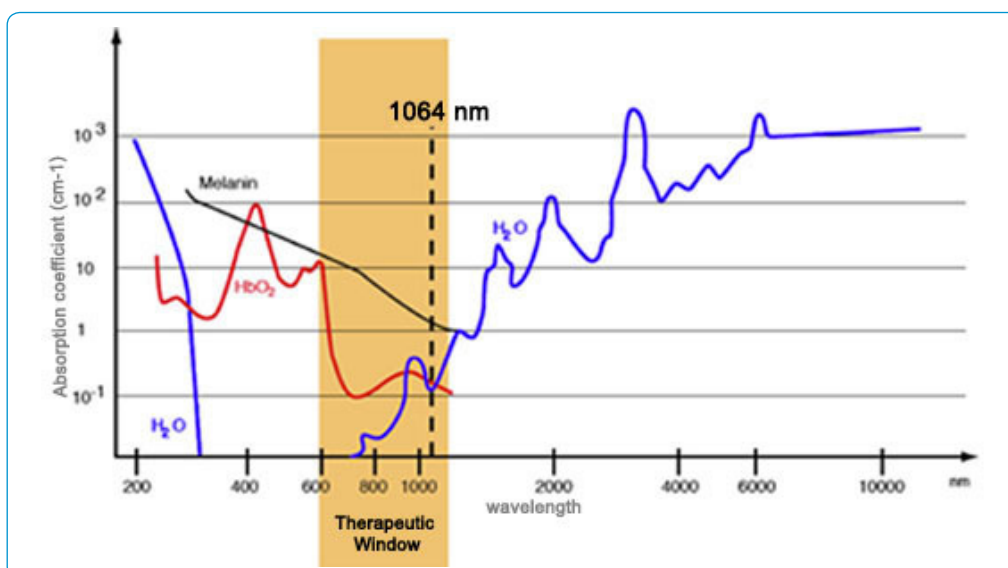
The diffusion theory gives an accurate description of light propagation in scattering media when scattering coefficient of tissue is much larger than the absorption coefficient. This is true for almost biological tissue in the so called "**Therapeutic window**" (also known as **near-infrared (NIR) window**) that defines the range of wavelengths from 650 to 1350 nm where absorption is small and optical penetration achieves the maximum levels. Since scattering increases the distance travelled by photons within tissue, the probability of photon absorption also increases.

Absorption coefficient spectra in water and other biological tissue constituents

Because scattering has weak dependence on wavelength in this spectral region (due to the relatively large size and heterogeneity of the scattering centers in tissue, the scattering coefficient decreases by a factor of 2 every 200nm), the therapeutic window is limited at a lower wavelength due to hemoglobin absorption (oxygenated HbO<sub>2</sub> and not oxygenated Hb) and at a upper wavelength due to water absorption

The light produced by laser with a wavelength of 1064nm represents an ideal compromise to obtain a good penetration depth and a sufficient tissue absorption depending on the tissue optical properties.

**Echolaser directly uses a laser emission at 1064 nm wavelength that has an excellent light penetration.**



**Graphic 1.** Absorption coefficient spectra in water and other biological tissue constituents

## Scientific & Educational Events Update



**Francesco Lonero**

Elesta Marketing Manager  
f.lonero-elesta@esaote.com




The Lighthouse of Genoa

On February 13<sup>th</sup> at the Institute of Internal Medicine and Medical Specialties, University of Genoa was held the scientific conference entitled **"The thyroid nodule, comparison of possible treatment options"**, aimed at Specialists in General Surgery, Endocrinology, Radiology, Nuclear Medicine, General Medicine and Family Physicians. Over 50 participants listened to 12 expert speakers who exposed and discussed topics of great interest that ranged from diagnostic imaging to comparison between minimally invasive techniques and surgery. Dr. Teresa Rago, Department of Endocrinology 1 - Pisa University, presented their results on laser ablation at 4 years follow-up.



Attendees and Speakers

Dr. Silvia Oddo, Department of Endocrinology - IST San Martino Genova University, presented the results of the first experiences on laser ablation. It was a success that crowned the efforts and commitment of the promoter Prof. Massimo Giusti.



Albano Lake

On 9<sup>th</sup> and 10<sup>th</sup> April, near the beautiful natural setting of Lake Albano, was held the first course **"Focus on US-guided diagnostic procedures and laser treatment of thyroid lesions"** in the International School of Thyroid Ultrasonography and Ultrasound-Assisted Procedures at the Departments of Endocrinology and Interventional Radiology of Regina Apostolorum Hospital (Albano Laziale).

6 participants from the USA, India, China, Portugal and Sweden attended the theoretical and practical sessions conducted by Prof. Papini and Dr. Bizzarri who focused topics such as ultrasound basics, imaging based thyroid nodules classification, minimally invasive therapies and procedures, with a large number of live fine needle aspirations, alcoholizations, core needle biopsies and laser echo-guided treatments.

Next edition will be held on September 17<sup>th</sup> and 19<sup>th</sup>: attention requests to date have almost filled the seats available!



The Class !

Echolaser news are available at  
<http://www.elesta-echolaser.com/en/rassegna-stampa/>

### Echolaser Club'contacts

Tel +39 055 8826807 – Fax +39 055 7766698  
e-mail [info@elesta-echolaser.com](mailto:info@elesta-echolaser.com)

### ModiLite

<http://modilite.info>

### Esaote S.p.A.

International Activities:

Via di Caciolle 15 50127 Florence, Italy  
Tel. +39 055 4229 1 Fax +39 055 4229 208  
[www.esaote.com](http://www.esaote.com)



### Elesta s.r.l.

Via Baldanzese 17 50041 Calenzano, Italy  
Tel. +39 055 8826807 Fax +39 055 7766698  
[www.elesta-echolaser.com](http://www.elesta-echolaser.com)

Echolaser News and any files transmitted with it are confidential. The EchoLaser members are authorized to view and make a single copy of parts of its content for offline, personal, non-commercial use. The content may not be sold, reproduced, or distributed without our written permission. Any third-party trademarks, service marks and logos are the property of their respective owners. Any further rights not specifically granted herein are reserved.