

See You There:

From 8th to 9th of April
In Montesilvano, Pescara,
Italy at the Grand Hotel
Adriatico Congress
**VII Giornate
Endocrinologiche
Abruzzesi - G.E.A.**

**From 21st to
22nd of April**
In Albano Laziale,
Rome, Italy at Regina
Apostolorum Hospital
**International
School of Thyroid
Ultrasonography and
Ultrasound-Assisted
Procedures** Focus on
US-guided diagnostic
procedures and laser
treatment of thyroid
lesions

**From 19th to
20th of May**
In Pisa, Italy at Palazzo
dei Congressi Congress
**Incontri Italiani di
Endocrinologia e
Metabolismo**

From 1st to 2nd of July
In Pisa, Italy at
Cisanello Hospital.
**International
Course of Thyroid
Ultrasonography and
Minimally Invasive
Procedures** Advanced
practical thyroid
ultrasound course: Focus
on US guided Fine Needle
Aspiration, Percutaneous
ethanol injection and
laser treatment of thyroid
nodules

Efficacy and Safety of Percutaneous Laser Ablation Therapy for Treatment of Large HCC

Abstract of the 49th A.I.S.F. - Italian Association for the Study of the Liver - Annual Meeting 2016 in Rome, 18 - 19 February 2016

Published on "Digestive and Liver Disease", an International Journal of Gastroenterology and Hepatology, Vol. 48 Supplement 1 (2016)

S. Camera¹, G.G. Di Costanzo², R. Tortora², L. Addario², F. Lampasi², M.T. Tartaglione², V. Cossiga¹,
L. Donnarumma¹, N. Caporaso¹, F. Morisco¹

¹Dipartimento di Medicina Clinica e Chirurgia, Università "Federico II", Napoli, Italy

²Unità di Epatologia, AORN "Cardarelli", Napoli, Italy

Percutaneous laser thermal ablation (LA) represents one of currently available loco-ablative techniques for the treatment of hepatocellular carcinoma (HCC).

This study aimed to analyze the efficacy and safety of LA in patient with large HCC.

Between January 2009 and December 2012, 53 cirrhotic patients (40/13 Male/Female; mean age 70, range 51–84 yrs; Child-Pugh A/B: 48/5, BCLC stage A/B: 29/24) with at least one nodule of HCC ≥ 40 mm treated with LA were enrolled at the Liver Unit of the "Cardarelli" Hospital of Naples.

Forty-one patients (77%) had a single nodule HCC, while 12 patients (23%) had a multinodular HCC. The median size of the main HCC nodule was 50 mm (range 40–75 mm). Response to therapy was evaluated with imaging techniques according to the mRECIST criteria.

Survival was calculated from the time of cancer diagnosis to death with values censored at the date of the last follow-up.

Thirty-five patients (66%) showed a complete response to LA, while only 18 patients (34%) showed a partial response; none showed stable or progressive disease after treatment.

The therapeutic efficacy was similar in nodules sized 40–50 mm in comparison to those larger than 50 mm.

The cumulative survival rates were 85.8% and 56.6% at 12 and 36 months, respectively.

The disease recurrence was observed in 13 patients (24%) after a median time of 16 months (range 5–40). The recurrence was not related to the size of main HCC nodule.

According to safety analysis, only 3 patients (<5%) showed post-ablation complications: fever and mild abdominal pain for a period of at least 10 days. In one patient the fever was associated with ascites and pleural effusion, both successfully treated with diuretic therapy.

LA could be considered an efficacious and safe therapeutic option in patients with difficult to treat large HCC.

Ultrasound-guided Laser Thermal Ablation for the Treatment of High-risk sites of Small Liver Cancer

WU Xiaomin, ZHOU Ping*, MA Shuhua, TIAN Shuangming, DENG Jin, ZHAO Yongfeng Department of Ultrasound, The Third Xiangya Hospital, Central South University, Changsha 410013, China.



*Corresponding Author: **Zhou Ping, MD. Ph.D.** Chairman of the Ultrasonic Medicine branch of HuNan Province of the Chinese Medical Association. Professor, Doctoral supervisor of Central South University. Director of Department of Ultrasound, The Third Xiangya Hospital, Central South University. E-mail address: zhouping1000@hotmail.com

J South Med Univ, 2016,36(1):120-125

Abstract

Objective

To investigate the clinical value of ultrasound-guided laser thermal ablation (LTA) in the treatment of small liver cancer at high-risk sites.

Methods

A total of 73 lesions were ablated with LTA in 68 patients with small liver cancer. Power was set at 5W and an energy between 1600J and 1800J was used for each optical fiber. After the operation, the rates of complete ablation were compared between patients with lesions of different sizes and at different sites using contrast-enhanced ultrasound and the complications were recorded during the follow-up.

Results

The complete ablation rates for carcinomas ≤ 1 cm, 1-2 cm, and 2-3 cm were 100%, 86.4%, and 82.7%, respectively, showing no significant differences among them ($P > 0.05$). The complete ablation rates of lesions were similar between the high-risk and low-risk groups (85.7% vs 92.1%; $P > 0.05$). The two groups showed no significant difference in the incidence of complications (9.1% vs 5.7%; $P > 0.05$). All complications are minor and acceptable, included 2 cases of abdominal dropsy, 2 cases of pleural effusion and one case of fever.

Conclusion

Ultrasound-guided LTA can be a good option for treatment of small liver cancers at high-risk sites.

Keywords:

laser thermal ablation; small liver cancer; contrast-enhanced ultrasound

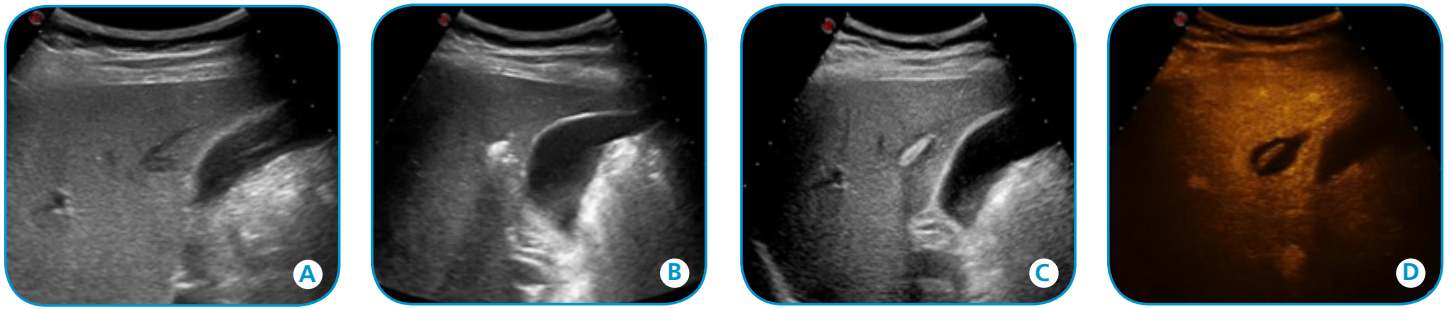


Fig.1: Representative ultrasound images showing complete ablation of hepatocellular carcinoma of 5 mm in a 49-year-old male patient. A nodular lesion was found in the S5 with a dimension of 4 mm × 5 mm, and was pathologically identified as HCC. **A:** A nodule <5 mm from the gallbladder, **B:** Gas covered nodule gradually in the process of laser ablation, **C:** Ultrasonogram of ablation lesion after LA procedure, **D:** Contrast enhanced ultrasound of the ablation lesion (three-phase had no enhancement; MI=0.1).

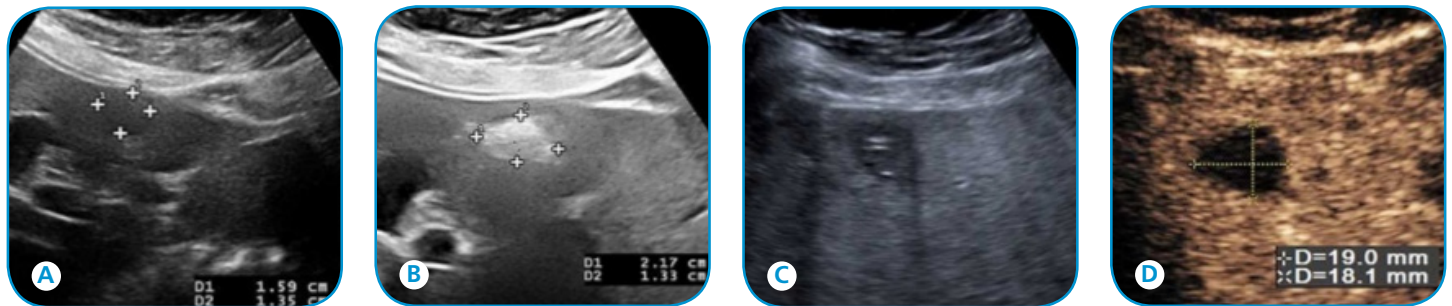


Fig.2: A representative case of complete ablation of breast cancer liver metastases of 16 mm in a 48-year-old female patient. The nodular lesion was located in the S4 with a dimension of 16 mm × 13 mm. **A:** A nodule <5 mm in the liver capsule and gallbladder; **B:** Gas covered nodule gradually in the process of laser ablation; **C:** Ultrasonogram of ablation lesion after LA procedure; **D:** Contrast-enhanced ultrasound of the ablated lesion. Three-phase had no enhancement (MI=0.1).

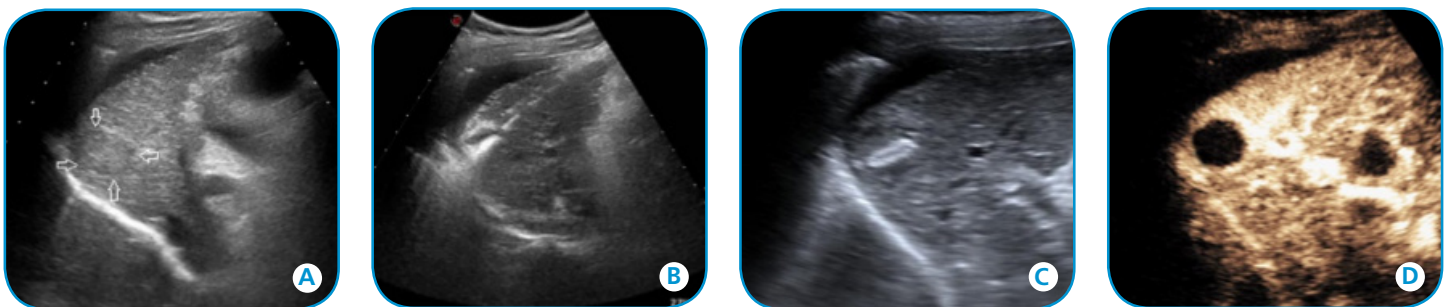


Fig.3: A representative case showing complete ablation of hepatocellular carcinoma of 21 mm in a 53-year-old male patient. A nodular lesion was found in the S6 with a dimension of 21 mm × 17 mm, and pathologically identified as HCC. **A:** nodule <5 mm in the diaphragm; **B:** Gas covered nodule gradually in the process of double needle laser ablation (two needle point distance was about 1.5 cm); **C:** Ultrasonogram of the ablated lesion after LA procedure; **D:** Contrast-enhanced ultrasound of the ablation lesion. Three-phase had no enhancement (MI=0.1).

Echocardiography-guided percutaneous per-ventricular laser ablation of ventricular septum: in vivo study in a canine model

He G¹, Sun C¹, Zhang X^{1,2}, Zuo L¹, Qin H¹, Zheng M¹, Zhou X³, Liu L⁴.

¹Ultrasound Department, Xijing Hospital, Fourth Military Medical University, Changle West Road 15 Hao, Xi'an, ShaanXi Province, 710032, China.

²Ultrasound Department, Ningxia Medical University, Yin Chuan, China.

³Ultrasound Department, Xijing Hospital, Fourth Military Medical University, Changle West Road 15 Hao, Xi'an, ShaanXi Province, 710032, China. zhouxd@fmmu.edu.cn.

⁴Ultrasound Department, Xijing Hospital, Fourth Military Medical University, Changle West Road 15 Hao, Xi'an, ShaanXi Province, 710032, China. liuliwen@fmmu.edu.cn.

Lasers Med Sci. 2016 Feb 9.

Abstract

Surgical myectomy and ethanol ablation are established intervention strategies for left ventricular outflow obstruction in hypertrophic cardiomyopathy. Safety and efficacy limitations of these interventions call for a minimally invasive, potentially safer, and more efficacious strategy. In this study, we aimed to evaluate the feasibility of echocardiography-guided percutaneous per-ventricular laser ablation of a ventricular septum in a canine model. Six domestic dogs were chosen for the study. A 21G needle was inserted into the right ventricle with its tip reaching the targeted basal to mid-septum, after which laser ablation was performed as follows: 1-W laser for 3 min (180 J) at the basal segment and 5 min (300 J) at middle segment of the septum, respectively. Echocardiography, blood chemistry tests, and pathology examination were performed to assess the results of laser ablation. No death or major complications, i.e., tamponade, pericardial effusion, or ventricular fibrillation, occurred. The laser-ablated areas were well demarcated in the results of the pathological examination. The diameters of the ablated regions were 4.42 ± 0.57 and 5.28 ± 0.83 mm for 3 and 5 min ablation, respectively. Pre-ablation and post-ablation, cardiac enzymes were found to increase significantly while no significant differences were found among M-mode, 2D (LVEF), pulsed-wave (PW) Doppler, and tissue Doppler imaging (TDI) measurements. Contrast echocardiography confirmed the perfusion defects in the ablated regions. Microscopically, the ablated myocardium showed coagulative changes and a sparse distribution of disappearing nuclei and an increase in eosinophil number were observed. Our study suggests that percutaneous and per-ventricular laser ablation of the septum is feasible, potentially safe and efficacious, and warrants further investigation and validation.

Keywords:

Laser ablation Septum Echocardiography Percutaneous Per-ventricular Intervention.

Note:

Guangbin He, Chao Sun and Xiangkong Zhang contributed equally to this work.

Take part to the Congress “VII Giornate Endocrinologiche Abruzzesi - G.E.A.”

On the 8th and 9th of April in Montesilvano, Pescara, the Congress “VII Giornate Endocrinologiche Abruzzesi - G.E.A.” will take place at the Grand Hotel Adriatico.



Coordinator and scientific responsible of the Congress is Prof. B. Raggiunti, Director of the U.O.C. of Endocrinology and M.M. San Liberatore Hospital, in Atri, Teramo.

We are glad to highlight on Friday 8th the second symposium on thyroid nodular pathology moderated by Prof. R. Guglielmi and Prof. P. Vitti and the third symposium “Terapia Citoriduttiva Tiroidea” in which Percutaneous Laser Ablation technique will be explained and discussed with the following opinion leaders: Prof. P. De Feo, Dr. C. Schiavone, Prof. B. Raggiunti, Dr. G. Achille, Dr. G. Gambelunghe, Dr. R. Cesareo, Dr. D. Tina, Prof. C.M. Pacella.

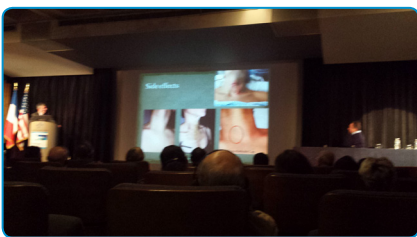
We would like also to advise the participation in the same date to the Keynote Lecture of Prof. E. Papini.

The participation to the event is free, the online registration is available at www.athenacongressi.it before the 31st of March, this include: access to the scientific events, ECM credits, congress kit, participation certificate, coffee break and working breakfast.

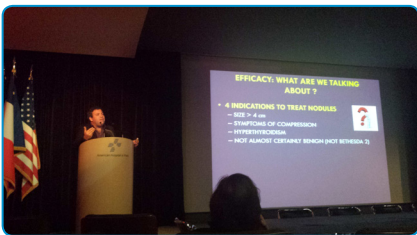
The Congress program is available at the following link:

<http://88.35.48.138/getFile.asp?idFile=214>

“Aux Frontières de la Prise en Charge des Nodules e des Cancers de la Thyroid” Congress



Dr. Monpeyssen and Dr. Bizzarri



Dr. Ghanassia

On January 22nd/23rd the Congress “Aux Frontières de la prise en charge des nodules e des cancers de la thyroid” was held at the American Hospital in Paris. The event was organized by Dr. Hervé Monpeyssen, Head of the Thyroid Unit of AHP and Dr. Patrick Aidan Chief of the Head and Neck Unit of AHP.

More than 70 doctors attended the Congress listening very-high level speakers (Dr. Jean Tramalloni, Dr. Giancarlo Bizzari, Dr. Gilles Russ, Prof. David Cooper, Prof. Jean Luis Wemeau, Prof. Laurence Leenhardt, Dr. Beatrix Cochand Priollet, Prof. Enrico Papini, Prof. Frédérique Savagner, Prof. Rafi Feinmesser, Dr. Emad Kandil, Dr. Balazs Lorincz, Prof. Paolo Miccoli, Dr. Andrea Frasoldati, Prof. Rossella Elisei), from several countries, that introduced topics in the fields of diagnosis, therapies, surgery and minimally invasive techniques. Elesta showed an EchoLaser system in the exhibition area, picking up a lot of interest of Congress attendees.



Elesta Booth



Sold out for the International School of Thyroid Ultrasonography and Ultrasound-Assisted Procedures Advanced Course

Sold out for the next Advanced Course of the International School of Thyroid Ultrasonography and Ultrasound-Assisted Procedures, "Focus on US-guided diagnostic procedures and laser treatment of thyroid lesions" that will take place on the 21st and 22nd of April in Albano Laziale (Rome, Italy) at the Department of Endocrinology and Metabolism, and Department of Diagnostic Imaging and Interventional Radiology of the Regina Apostolorum Hospital.

This live educational course will put at learners disposal up-to-date knowledge on thyroid ultrasonography and on its novel applications such as laser treatment for benign nodules. Aim of the course is let the attendant to be able to:


- Recognize US patterns of thyroid nodules suggestive of malignancy
- Refine the execution methods for fine needle aspiration biopsy on thyroid nodules
- Apply novel alternative interventional approaches to treat benign thyroid nodules and selected thyroid malignancies.

Moreover the Participants may have, upon request, a 3-day stage period at Interventional Procedure Unit during year 2017.

Scientific Organisers are:




Dr. G. Bizzarri, Chief of Department of Diagnostic Imaging and Interventional Radiology, at Regina Apostolorum Hospital



Prof. E. Papini, Chief of Department of Endocrinology and Metabolism, at Regina Apostolorum Hospital

Reservation for the course of September 2016 are already underway.

"Tractament Percutani de nòduls tiroïdal benignes: 1^o Edició" Course in Barcelona



Hospital Clinic in Barcelona was the venue where the Course "Tractament Percutani de nòduls tiroïdal benignes: 1^o Edició" was held on 18th/19th of January.

The Course was organized by Dr. Felicia Alexandra Hanzu and Dr. Mireia Mora from Endocrinology Dept. (headed by Dr. Irene Halperin) and Dr. Mattia Squarcia from Neuroradiology Dept. (headed by Dr. González Berenguer). The event was addressed to a class of 6 doctors specialized in endocrinology or radiology with experience in thyroid ultrasound. All key relevant topics on thyroid laser ablation were introduced

starting from a general overview on minimally invasive techniques applied on thyroid nodules (Prof. Enrico Papini from Regina Apostolorum Hospital in Rome) and then proceeding with the eligibility criteria (Dr. Irene Halperin from HC), the ultrasound anatomy of the neck (Dr. Mattia Squarcia from HC), the anesthesiologist point of view (Dr. Enrique Carrera from HC), the comparison between the classic protocol and the Light & Flight technique developed at HC (Dr. Felicia Alexandra Hanzu from HC) and Laser vs RF comparison (Dr. Mireia Mora from HC).

The Course included a highly appreciated "hands-on" session of laser ablation on "in vitro" tissues and, at the end, the participants attended live sessions on patients with the support of a live camera.





Echolaser donation to the Savigliano Hospital from "Amici dell'Ospedale" Association

The "Amici dell'Ospedale" Association donated an Echolaser to the Savigliano Hospital to perform the thermo-ablation of thyroid benign nodules with a minimally invasive approach.



Gloria Chiozza, Clinical Director of the Asl CN1 illustrated: "The aim is to increase the offer concerning diagnosis and therapy of thyroid diseases. We arrived to this conclusion through various steps: an educational investment to enhance the echographic diagnosis on the

neck, purchase of a top quality ultrasound machine and finally the donation, from the Amici dell'Ospedale Association, of a laser connectable to the ultrasound machine for the thermo-ablation".

Toni Pazziaia, Director of the Otorinolaringoiatry who is part of this project, said: "Today the illustrated approach creates no conflicts between clinicians and surgeon, because there are patients who, for various reasons, can be treated with a solution that doesn't involve a surgical intervention".

The Italian press release can be read at this LINK.

<http://www.ideawebtv.it/attualita-fossanese-saviglianese/35557-ospedale-di-savigliano-presentato-il-nuovo-laser-per-trattare-il-nodo-tiroideo>

Echolaser news are available at
<http://www.elesta-echolaser.com/en/rassegna-stampa/>

Echolaser Club'contacts
Tel +39 055 8826807 – Fax +39 055 7766698
e-mail info@elesta-echolaser.com

ModiLite
<http://modilite.info>

Esaote S.p.A.
International Activities:
Via di Caciolle 15 50127 Florence, Italy
Tel. +39 055 4229 1 Fax +39 055 4229 208
www.esaote.com



Elesta s.r.l.
Via Baldanzese 17 50041 Calenzano, Italy
Tel. +39 055 8826807 Fax +39 055 7766698
www.elesta-echolaser.com

Echolaser News and any files transmitted with it are confidential. The EchoLaser members are authorized to view and make a single copy of parts of its content for offline, personal, non-commercial use. The content may not be sold, reproduced, or distributed without our written permission. Any third-party trademarks, service marks and logos are the property of their respective owners. Any further rights not specifically granted herein are reserved.